



**PATIENT**

Sancho Johnson

**SPECIES**

Canine

**BREED**

American Bulldog

**SEX**

Male Neutered

**AGE**

8.4 years

**WEIGHT**

57lbs

**PRESENTING CLINICAL SIGNS**

History: Cough - lifelong. On 1) Gabapentin 400mg night before CUS and morning of CUS. 2) Trazodone 200 mg night before CUS and morning of CUS Radiography Results: 3 view T. -Abnormal PE/Chem/CBC/UA Results: BNP: 1594 (0-900), mild non renal proteinuria.

**ECHOCARDIOGRAM FINDINGS**

2D, m-mode, color flow and Doppler imaging is available.

**Left ventricle:** The LV diameter is normal with adequate myocardial function. LV wall thicknesses are normal.

**Left atrium:** The left atrium is normal.

**Mitral valve:** The mitral valve is diffusely thickened with minimal prolapse into the left atrial lumen. Mild eccentric mitral regurgitation with a normal velocity.

**Aortic valve/aorta:** The aortic valve is normal in morphology and mobility. Normal aortic outflow velocity; laminar flow. No aortic insufficiency.

**Right ventricle:** Normal right ventricular diameter and morphology.

**Right atrium:** No RA enlargement.

**Tricuspid valve:** The tricuspid valve appears mildly thickened with mild tricuspid regurgitation. Velocity consistent with early pulmonary hypertension.

**Pulmonic valve/pulmonary artery:** The pulmonic valve is normal in morphology and mobility. No pulmonic insufficiency. Normal RVOT velocity; laminar flow.

**Pericardium/other:** No pericardial or pleural effusion noted. No obvious cardiac masses.

**Heart rhythm:** ECG reveals a sinus rhythm with an average HR of 150bpm.

**INTERPRETED BY**

Maggie Machen  
Lamy, DVM  
DACVIM (Cardiology)

**IMAGING**

**PERFORMED BY**

Pamela Harrigan,  
RDCS

**2-Dimensional Measurements**

|                    |     |
|--------------------|-----|
| Ao diam (cm)       | 2.4 |
| LA diam (cm)       | 2.8 |
| LA:Ao (Swe)        | 1.2 |
| IVS thickness (cm) | 0.9 |
| LVID diastole (cm) | 1.3 |
| PW thickness (cm)  | 0.9 |
| LVID systole (cm)  | 3.2 |
| FS (%)             | 26  |

**Doppler Measurements**

|                |     |
|----------------|-----|
| PV Vmax (m/s)  | 0.8 |
| AoV Vmax (m/s) | 1.2 |
| MR Vmax (m/s)  | 5.1 |
| TR Vmax (m/s)  | 2.8 |
| TR PG (mmHg)   | 32  |

**INTERPRETATION OF THE FINDINGS**

Chronic degenerative valve disease causing mild mitral and tricuspid regurgitation. Lack of significant left a or right atrial enlargement indicates the current risk for complication is low. Early pulmonary hypertension is noted, which is likely secondary to a reported cough. No additional issues are identified.

**HOSPITAL NAME**

Foster Veterinary  
Clinic

**REFERRING VET**

Dr. Hattan

**INVOICE**

32060

**DATE**

8/1/23

Given these findings, the cough is unlikely to be cardiac in origin and primary respiratory causes should be considered. Consider further respiratory work up/treatment (hydrocodone, taper course of steroids, Enrofloxacin, TTW/BAL, etc.).

No medications are indicated based upon these findings. Assessment of progression in the future will help predict long term prognosis, which is highly variable at this stage (B1).



**PATIENT**

Sancho Johnson

**SPECIES**

Canine

**BREED**

American Bulldog

**SEX**

Male Neutered

**AGE**

8.4 years

**WEIGHT**

57lbs

**INTERPRETED BY**

Maggie Machen  
 Lamy, DVM  
 DACVIM (Cardiology)

**IMAGING PERFORMED BY**

Pamela Harrigan,  
 RDMS

**HOSPITAL NAME**

Foster Veterinary  
 Clinic

**REFERRING VET**

Dr. Hattan

**INVOICE**

32060

**DATE**

8/1/23

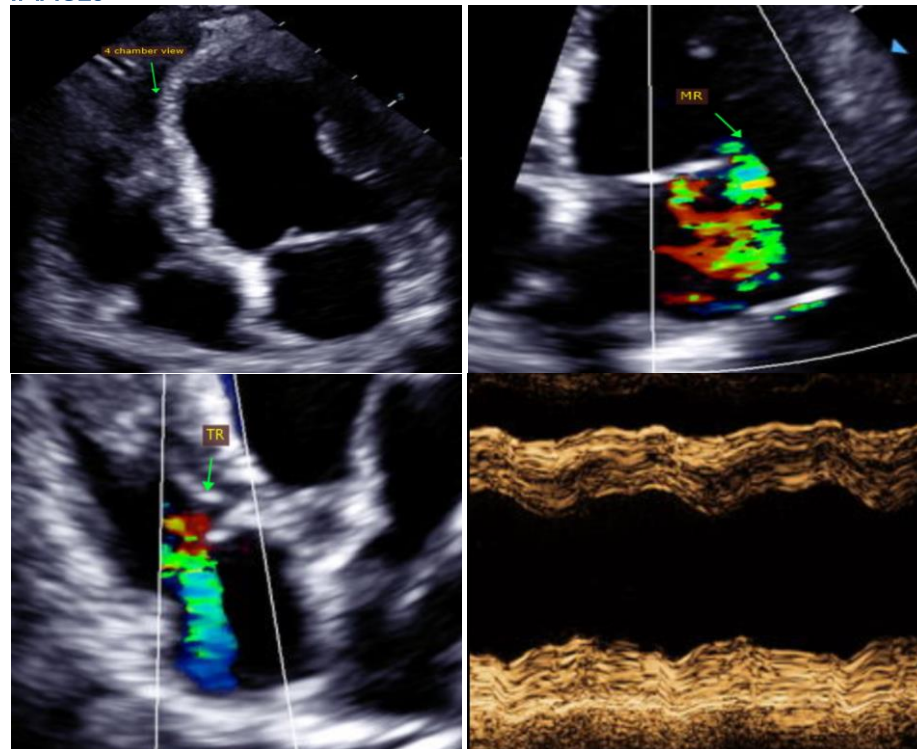
**RECOMMENDATIONS**

- No cardiac medications are indicated.
- Consider cough evaluation/treatment as discussed.
- Omega fatty acid supplementation and mild salt restriction may be of some long-term benefit.
- Anesthetic risk is considered mild if needed. Cardiac protective drug choices (opioid/benzodiazepine premedication, propofol or alfaxalone induction, isoflurane gas) are recommended. Pre-oxygenate for 5-10 minutes prior to induction. Monitor for arrhythmias, hypotension, and hypoxia both intra and post-operatively and intervene as necessary. Mild IV fluid restriction is recommended to avoid fluid overload. Avoid heart rate stimulating drugs such as atropine unless clinically indicated.
- Monitor for development of a cough, labored breathing, exercise intolerance or collapse episodes.

**PLAN**

- Recommend conservative monitoring with a recheck echocardiogram in 6-12 months, sooner if any development of clinical signs.

**IMAGES**





**PATIENT**

Sancho Johnson

The information and recommendations provided are based on the images presented by the referring veterinarian. No evaluation can be communicated regarding pathology that was not visible in the image/video clips provided.

**SPECIES**

Canine

Thank you for this referral. This report was generated using transcription software, and minor dictation errors may be present. If the clinical or image interpretation does not parallel your findings or if I can be of any further assistance, please contact me.

**BREED**

American Bulldog

Maggie Machen Lamy, DVM  
Diplomate of the American College of Veterinary Internal Medicine (Cardiology)  
info@sonopath.com

**SEX**

Male Neutered

Echocardiogram performed by: Pamela Harrigan, RDCS  
Pet Animal Ultrasound Service ([4paus.com](http://4paus.com))

**AGE**

8.4 years

**WEIGHT**

57lbs

**INTERPRETED BY**

Maggie Machen  
Lamy, DVM  
DACVIM (Cardiology)

**IMAGING  
PERFORMED BY**

Pamela Harrigan,  
RDCS

**HOSPITAL NAME**

Foster Veterinary  
Clinic

**REFERRING VET**

Dr. Hattan

**INVOICE**

32060

**DATE**

8/1/23